

## The Stool Color Card as a Screening Tool for Biliary Atresia in the Digital Version of the Portuguese Child and Youth Health Booklet

### O Cartão de Cores das Fezes como Instrumento de Rastreio da Atrésia Biliar na Versão Digital do Boletim de Saúde Infantil e Juvenil Português

**Keywords:** Biliary Atresia/diagnosis; Fezes; Jaundice, Neonatal; Neonatal Screening

**Palavras-chave:** Atrésia das Vias Biliares/diagnóstico; Fezes; Ictericia Neonatal; Rastreio Neonatal

Dear Editor

Biliary atresia (BA) is a rare entity (incidence in Europe of 1/18 000 live births) leading to great morbidity and mortality and represents the first indication for pediatric liver transplantation.<sup>1</sup> The long-term prognosis depends on the timing of bile flow restoration (Kasai portoenterostomy). One of the major determining factors of prognosis and survival of the native liver is surgical intervention before 45 days of life.<sup>2</sup>

Taiwan has one of the highest incidence rates of BA in the world. Therefore, a universal screening program was started there in 2002, using a validated stool color card (SCC). Subsequently, in 2011, it was observed that the median age of patients undergoing Kasai portoenterostomy decreased substantially, thus improving prognosis.<sup>3</sup> Meanwhile, other countries have demonstrated the cost-effectiveness of this tool,<sup>4</sup> and some have already started using it as a teaching and surveillance tool, by enrolling parents and caregivers. In Portugal, and as far as we know, there have been no initiatives at the level of the central healthcare system on this matter.

The SCC was originally created by Prof. Mei-Hwei Chang and her team, from the National University of Tai-

wan Medical College. It includes nine stool-colored images: three with normal colors and six with abnormal colors, which are considered red flags requiring urgent observation of the newborn/infant by Pediatricians.

A study performed in Northern Portugal has identified a significant percentage of healthcare professionals with clinical practices that may delay recognition of BA.<sup>5</sup> Recently, we have obtained written permission from both Prof. Mei-Hwei Chang and the Taiwan Ministry of Health and Health Promotion Administration to use the original SCC and its validated images for the purposes of a screening program in Portugal.

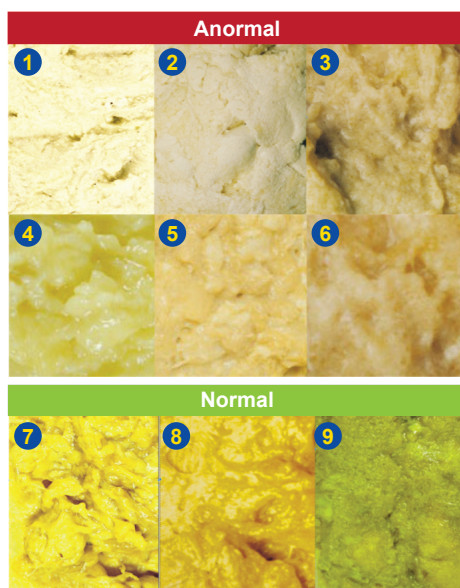
We propose the use of SCC as a teaching tool for parents at the time of discharge from the maternity hospital, and the inclusion of an early ambulatory screening in the first two visits after discharge by inserting the SCC into the Child and Youth Health Booklet. If the Portuguese Directorate-General of Health will convert the current paper booklet into a digital format, as it has been preliminarily admitted, we propose that a SCC should be part of this update (Fig. 1) and that a digital version should be accessible to both parents and caregivers, for example, through a web link or an app. In this scenario, the outcome of the implementation of this practice must be validated and a referral network should be implemented.

#### AUTHORS CONTRIBUTION

JA: Requested for permission to use the original SCC and its validated images, drafted the manuscript and approved its final version.

MT: Contributed with intellectual insights to the work, critically reviewed the manuscript and approved its final version.

ESS: Designed the work, supervised the request for



#### Vigie a cor das fezes do seu bebé Rastreio da atrésia das vias biliares

- 1ª causa de transplante hepático em idade pediátrica -

Nos primeiros dois meses de vida **vigie** no seu bebé:

##### • A cor dos olhos e pele.

Se estiverem amarelos (**ictericia**) recorra ao seu Centro de Saúde ou ao seu Pediatra.

Se a icterícia persistir **para além dos 14 dias de vida**, recorra outra vez ao seu médico.

##### • A cor das fezes.

Se o seu bebé tiver **ictericia e fezes descoradas** (amarelo ou verde pálido, cinzento ou branco - cores 1 a 6) pode/deve recorrer directamente à Urgência de Pediatria hospitalar.

Agradecemos ao Health Promotion, Ministry of Health and Welfare, Taiwan e à Professora Mei-Hwei Chang, College of Medicine, National Taiwan University, por autorizarem o do seu Stool Color Card.

Figure 1 – Portuguese stool color card for screening biliary atresia in newborns and infants

permission to use the original SCC and its validated images, critically reviewed the manuscript and approved its final version.

AIL: Designed the work, critically reviewed the manuscript and approved its final version.

### PROTECTION OF HUMANS AND ANIMALS

The authors declare that the procedures were followed according to the regulations established by the Clinical Research and Ethics Committee and to the Helsinki Declaration of the World Medical Association updated in 2013.

### REFERENCES

1. Fanna M, Masson G, Capito C, Girard M, Guerin F, Hermeziu B, et al. Management of biliary atresia in France 1986 to 2015: long-term results. *J Pediatr Gastroenterol Nutr.* 2019;69:416-24.
2. Serinet MO, Wildhaber B, Broue P, Lachaux A, Sarles J, Jacquemin E, et al. Impact of age at Kasai operation on its results in late childhood and adolescence: a rational basis for biliary atresia screening. *Pediatrics.* 2009;123:1280-6.
3. Lien TH, Chang MH, Wu JF, Chen HL, Lee HC, Chen AC, et al. Effects of the infant stool color card screening program on 5-year outcome of

### DATA CONFIDENTIALITY

The authors declare having followed the protocols in use at their working center regarding patients' data publication.

### COMPETING INTERESTS

The authors have declared that no competing interests exist.

### FUNDING SOURCES

This research received no specific grant from any funding agency in the public, commercial, or not-for-profit sectors.

4. Mogul D, Zhou M, Intihar P, Schwarz K, Frick K. Cost-effective analysis of screening for biliary atresia with the stool color card. *J Pediatr Gastroenterol Nutr.* 2015;60:91-8.
5. Santos Silva E, Moreira Silva H, Azevedo Lijnzaat L, Melo C, Costa E, Martins E, et al. Clinical practices among healthcare professionals concerning neonatal jaundice and pale stools. *Eur J Pediatr.* 2017;176:361-9.

Joanna ASHWORTH<sup>1</sup>, Marta TAVARES<sup>2</sup>, Ermelinda SANTOS SILVA<sup>2,3,4</sup>, Ana Isabel LOPES<sup>5,6</sup>

1. Paediatrics Division. Child and Adolescent Department. Centro Materno-Infantil do Norte. Centro Hospitalar Universitário do Porto. Porto. Portugal.
2. Gastroenterology Unit. Pediatrics Division. Child and Adolescent Department. Centro Materno-Infantil do Norte. Centro Hospitalar Universitário do Porto. Porto. Portugal.
3. Instituto de Ciências Biomédicas Abel Salazar. Universidade do Porto. Porto. Portugal.
4. Laboratory of Biochemistry. Department of Biological Sciences. Faculdade de Farmácia. Universidade do Porto. Porto. Portugal.
5. Clínica Universitária de Pediatria. Faculdade de Medicina. Universidade de Lisboa. Lisboa. Portugal.
6. Paediatrics Gastroenterology Unit. Paediatrics Department. Hospital Universitário de Santa Maria. Centro Hospitalar Lisboa Norte. Lisboa. Portugal.

Autor correspondente: Ermelinda Santos Silva. [ermelinda.dca@chporto.min-saude.pt](mailto:ermelinda.dca@chporto.min-saude.pt)

Recebido: 06 de junho de 2021 - Aceite: 07 de junho de 2021 - *Online issue published:* 16 de julho de 2021 - *Online issue published:* 01 de setembro de 2021

Copyright © Ordem dos Médicos 2021

<https://doi.org/10.20344/amp.16679>

